



Avian Leucosis Complex

Introduction

Avian Leukosis Complex (ALC) is a complex of viral diseases with various manifestations such as lymphoid leukosis, myeloblastosis or myelocytomatosis (Type J), erythroblastosis, osteopetrosis, myxosarcomas, fibrosarcomas, other tumours caused by avian leucosis virus (ALV). ALV belongs to the Alpharetrovirus genus of the family Retroviridae. It is divided into subgroups A, B, C, D and J as exogenous and E, F, G, H and I as endogenous, depending on their viral envelope proteins which determine immune response and host range. ALC affects chickens worldwide with susceptibility varying considerably among different poultry species. However, it infects mainly chickens but can also infect pheasants, partridges and quail. It generally affects the chickens of approximately 16 week of age and older. The mortality due to ALC accounts for 1-2% of birds, with occasional losses of $\geq 20\%$.

Disease Transmission

Avian Leukosis Complex can be transmitted horizontally and vertically. Horizontal transmission (spread from bird to bird) can also occur by the faecal-oral route, especially in young birds. The virus can be vertically transmitted (passed directly from parent to offspring). Hens are able to shed the virus or viral components into eggs. Chickens infected at hatching shed virus their entire lives.

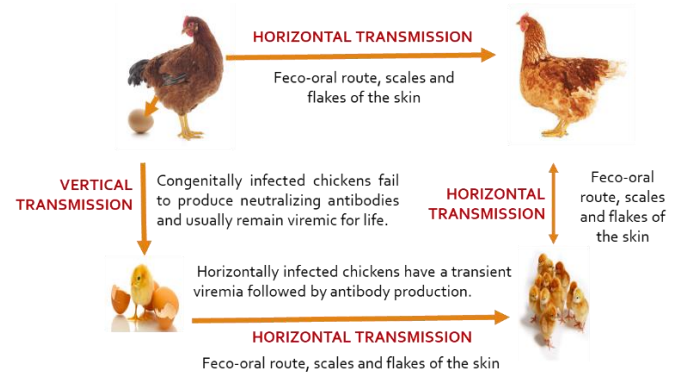


Figure 1 Mode of transmission of ALC.

Symptoms

In many of the cases, the birds remain asymptomatic. However, loss of appetite, weakness, diarrhea, dehydration, weight loss, enlarged abdomen (due to enlarged liver) and persistent low mortality may be seen. Infected birds may not necessarily develop tumours, but they may lay fewer eggs.

ALC in the context of Nepal

The disease status of ALC in Nepal is not much recorded and reported. However, field veterinarians have been reported the presence of disease since many years. Central Veterinary Laboratory (CVL) has also encountered the cases since many years, however, number of cases of ALC has much increased these days, especially in local hens and pheasants. Below are the detail cases of ALC brought at CLV during the first three month of the fiscal year 2078/079.

Diagnosis

Currently, several methods are available for the diagnosis of ALC. Standard criteria is based on history and clinical signs, gross pathology and histopathology. Similarly, advanced criteria are based on serological tests (ELISA), virus isolation and polymerase chain reaction (PCR). Among them, the PCR has been found to be specific and sensitive comparative to other tests. However, at CVL we diagnose it by post mortem lesions and ELISA test.

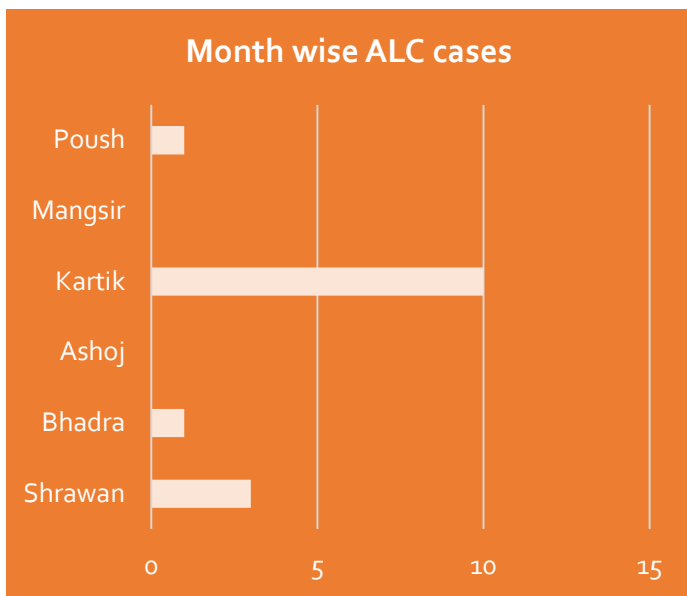


Figure 2 Month wise ALC cases at CVL.

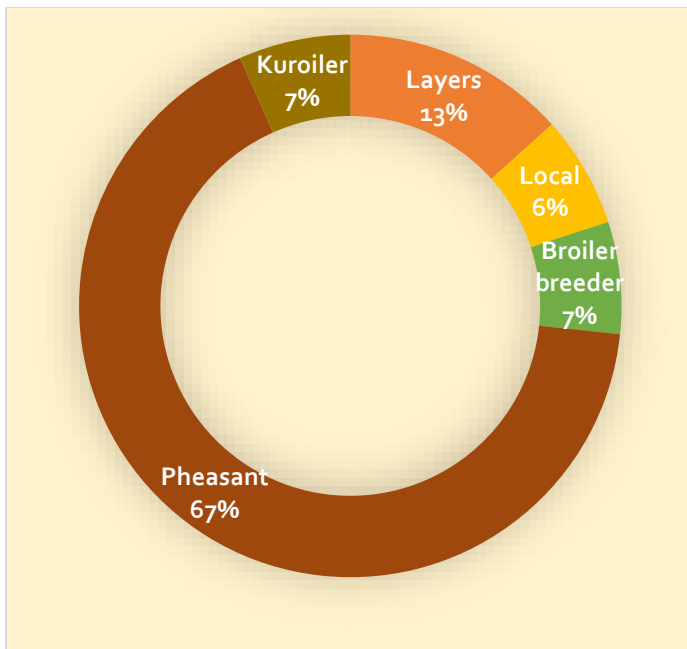


Fig. 3 Poultry type wise ALC cases.

Post-mortem Lesions

Most common post-mortem lesions observed in local poultry are: hepatomegaly with varying degree of tumors in liver, splenomegaly with diffused necrosis. Most common lesions in pheasants are tumors on skin and muscles. Mortality rates in local poultry are very low (1-2 birds per day to per weeks) but continuous mortality and high mortality observed in pheasants. Many literatures suggest that tumors on skin and muscle are generally absent in ALC. However, we observed numbers of tumors on skin and muscle in pheasants.

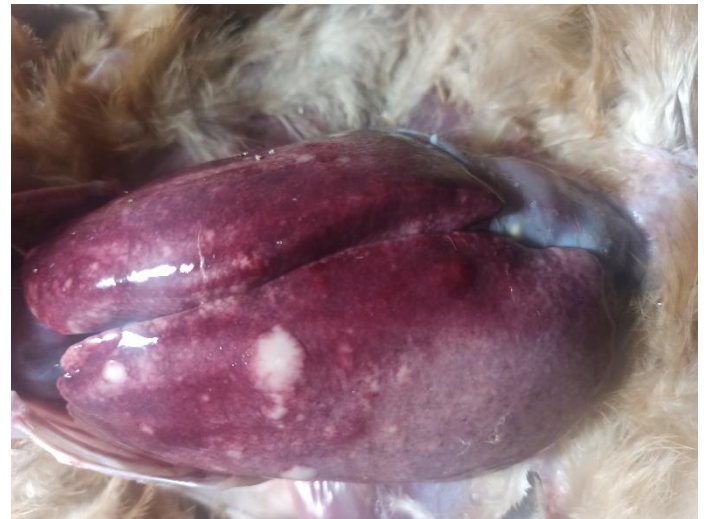

Fig. 4 Hepatomegaly with diffused tumors. (Kuroiler)

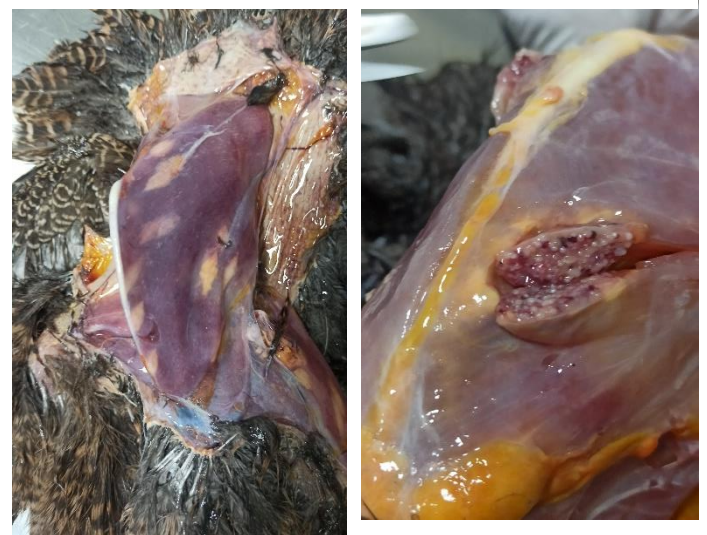

Fig. 5 Presence of tumors on chest muscles. (Pheasant)

Differential Diagnosis

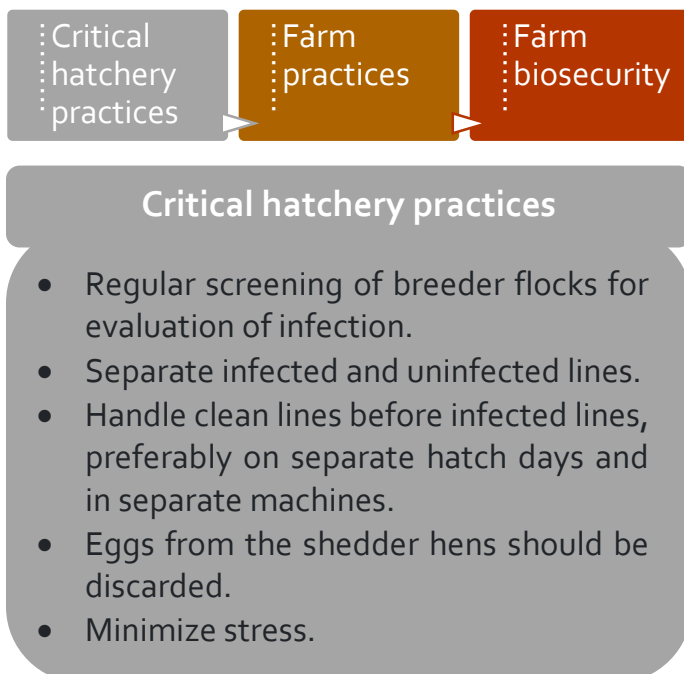
It is very important to differentiate ALC with few other poultry diseases. Marek's Disease (MD) is one of the most important disease to be differentiated from ALC. MD generally affects chicken below 16 weeks of age whereas ALC affects chicken above 16 weeks. Tumors on skin are absent in ALC whereas it is very frequent in MD. Central nervous system (paralysis) is affected in MD while it remains unaffected in ALC.

Treatment

There is no any specific treatment for ALC.

Prevention and Control

As discussed earlier, ALC is primarily a vertically transmitted disease. Thus, it is very important to identify breeder farms free from ALC. Vaccines are not commercially available to use it in Nepal. So, it is very important to follow the preventive and control measures to keep the poultry farm free from disease. Below are three basic approaches for the prevention and control of ALC in the farm and hatcheries.



Farm practices

- Brood and rear lines separately and maintain separate for as long as possible.
- Minimize group sizes.
- Vaccination with recombinant vaccines.
- Avoid migration errors (birds unintentionally moving between pens).

Farm biosecurity

- Regular disinfection in and outside the farm.
- Use of footbath in the gate of the farm.
- Restrict the movement of litter and other equipment of the infected farm.

References

Gowda, R. N. S. (2012) Outlines of Poultry Diseases, Poultry punch Publications Pvt. Ltd, New Delhi, India

MSD Veterinary Manual (2022) Retrieved from the website:

www.msddvetmanual.com/poultry/neoplasms/lymphoid-leukosis-in-poultry

The Poultry Site (2022) Retrieved from the website:

www.thepoultrysite.com/disease-guide/avian-leukosis-lymphoid-leukosis-leukosis-sarkoma-group

Poultry DVM (2022) Retrieved form the website:

www.poultrydvm.com/condition/lymphoid-leukosis

Pirbright (2022) Retrieved from the website:

www.pirbright.ac.uk/viruses/avian-leukosis-virus

Acknowledgements

- Internee students of HICAST
- Poultry farmers

जानकारी

पुशपन्छीहरूमा लाग्ने रोगहरूको प्रयोगशाला परिक्षणका लागि नमूना संकलन गर्ने तथा संरक्षण र सम्प्रेषण

क्र.स.	रोगको नाम	उपयुक्त नमूना संकलन	संरक्षण र सम्प्रेषण
१	लम्पि स्किन डिजिज	छालामा हुने ग्रिखा घाउको पाप्रा तन्तु वा स्वाव,	भि.टि.एम.वा पि.वि.एस. १०%Glycerine मा राखी आईस सहितको कुल बक्समा राखेर पठाउने।
		रगत	३ ml EDTA मा नमूना लिई आईस सहितको कुल बक्समा राखेर पठाउने।
		सिरम	२ ml सिरम को नमूना लिई आईस सहितको कुल बक्समा राखेर पठाउने।
२	पि.पि.आर.(PPR)	आँखा नाकबाट निस्के को श्रावको स्वाव (Ocular/Nasal Swab) मरेको भेडा बाखाको लिम्फनोड, फियो , फोक्सो , कले जो आदि	0.5 –1.0 ml P.B.S. भायलमा राखी कूलबक्समा Ice Pack समेत राखेर पठाउने Sterile Bottle वा Zip Lock Bag मा राखी कूलबक्समा Ice Pack समेत राखेर पठाउने
३	पि.आर .आर .एस (PPRRS)	सिरम	सिरम भायलमा राखी कूलबक्समा Ice Pack समेत राखेर पठाउने
४	क्लासिकल सवाईन फिवर र अफ्रिकन सवाईन फिवर -CSF and ASF	मरेको बंगुर सुंगरको लिम्फनोड, फियो , फोक्सो , कलेजो आदि रगत र सिरम	Sterile Bottle वा Zip Lock Bag मा राखी कूलबक्समा Ice Pack समेत राखेर पठाउने रगत EDTA भाईल र सिरम सिरम भायलमा राखी कूलबक्समा Ice Pack समेत राखेर पठाउने
५	वर्ड फ्लू (AI) र रानीखेत रोग (ND)	Tracheal / Swab / Cloacal Swab (जंगली पन्छीहरूको सुली/सुलीको स्वाव) मरेको कुखुरा वा अन्य मरेको पन्छी	0.5 –1.0 ml P.B.S. भायलमा राखी कूलबक्समा Ice Pack समेत राखेर पठाउने
६	रेबिज (Rabies)	मरेको पशुको गिदी वा सिङ्गे टाउका	गिदीलाई Sterile Bottle मा र टाउको लाई प्लास्टिक ब्यागमा प्याक गरी कूलबक्समा Ice Pack समेत राखेर पठाउने
७	ग्ल्यान्डर्स (Glanders)	घाउहरूबाट निस्कने पिप/स्वाव/तन्त	Sterile Bottle वा भायलमा 0.5 –1.0 ml P.B.S. राखी कूलबक्समा Ice Pack समेत राखेर पठाउने
८	थुनेलो (Mastitis)	दुधको नमूना	प्रत्येक थुनको १०-१५ml दुधको नमूना अलग अलग Sterile Bottle मा राखी कूलबक्समा Ice Pack समेत राखेर पठाउने
९	ब्रुसेलोसिस (Brucellosis)	पशु तृहेको ३ हप्ता पछिको सिरम	सिरम भायलमा राखी कूलबक्समा Ice Pack समेत राखेर पठाउने



नेपाल सरकार

कृषि तथा पशुपन्छी विकास मन्त्रालय

पशु सेवा विभाग

केन्द्रीय पशुपन्छी रोग अन्वेषण प्रयोगशाला

त्रिपुरेश्वर, काठमाण्डौं